

Inflammatory Skin Pathology

David Frishberg, M.D., Cedars Sinai (moderator)
Bonnie Balzer, M.D., Ph.D., Cedars Sinai
David Cassarino, M.D., Ph.D., UCLA
G. Peter Sarantopoulos, M.D., UCLA
Joseph Hillman, M.D., UCLA

Los Angeles Society of Pathologists
April 8, 2008

Acknowledgements

- ▶ A. Bernard Ackerman. *Histologic Diagnosis of Inflammatory Skin Diseases. An Algorithmic Method Based on Pattern Analysis.*
- ▶ John Muir, Tosh Gregg, and Peter Aschwanden. *How to Keep Your Volkswagon Alive. A Manual of Step by Step Procedures for the Compleat Idiot.*

Inflammatory Skin Pathology

- ▶ Introduction – Dr. Frishberg
- ▶ Case # 1 – Dr. Frishberg
- ▶ Case # 2 – Dr. Cassarino
- ▶ Case # 3 – Dr. Sarantopolous
- ▶ Case # 4 – Dr. Hillman
- ▶ Case # 5 – Dr. Balzer

Inflammatory Dermatopathology by Pattern and Algorithm

- ▶ Steps
 - Categorize the pattern
 - Assess the inflammatory cell population
 - Look for specific findings that direct the algorithm as far as it can be taken (analogy to SOAP notes in clinical medicine)
 - Correlate the histologic assessment with known clinical information

Inflammatory Dermatopathology by Pattern and Algorithm

- ▶ Superficial Perivascular Dermatitis
- ▶ Superficial and Deep Perivascular Dermatitis
- ▶ Nodular and Diffuse Dermatitis
- ▶ Panniculitis
- ▶ Vasculitis
- ▶ Folliculitis and Perifolliculitis
- ▶ Intraepidermal Vesicular and Pustular Dermatitis
- ▶ Subepidermal Vesicular Dermatitis

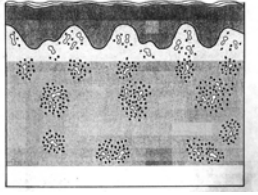
Inflammatory Dermatopathology by Pattern and Algorithm

- ▶ Superficial Perivascular Dermatitis
 - No epidermal involvement
 - Interface
 - Ballooning
 - Spongiotic
 - Psoriasiform



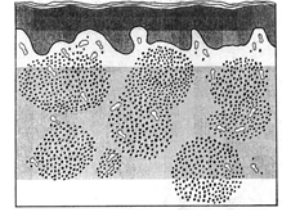
Inflammatory Dermatopathology by Pattern and Algorithm

- ▶ Superficial and Deep Perivascular Dermatitis
 - No epidermal involvement
 - Interface
 - Ballooning
 - Spongiotic
 - Psoriasiform



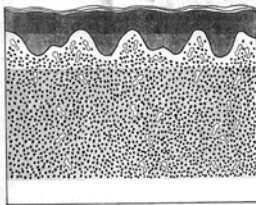
Inflammatory Dermatopathology by Pattern and Algorithm

- ▶ Nodular Dermatitis
 - Lymphocytes predominate
 - Neutrophils predominate
 - Neutrophils, eosinophils, and plasma cell prominent
 - Eosinophils prominent
 - Histiocytes predominate



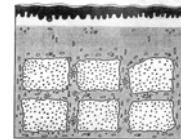

Inflammatory Dermatopathology by Pattern and Algorithm

- ▶ Diffuse dermatitis
 - Lymphocytes predominate
 - Neutrophils predominate
 - Neutrophils, and eosinophils prominent
 - Plasma cell prominent
 - Mast cells predominate
 - Histiocytes predominate



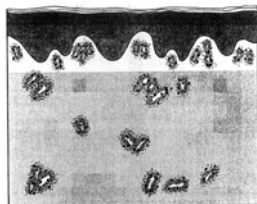
Inflammatory Dermatopathology by Pattern and Algorithm

- ▶ Panniculitis
 - Mostly septal
 - Mostly lobular



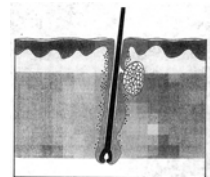
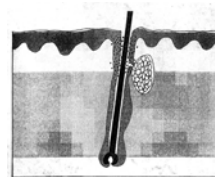
Inflammatory Dermatopathology by Pattern and Algorithm

- ▶ Vasculitis



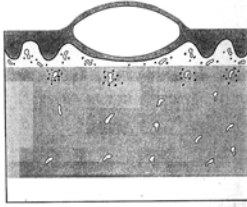
Inflammatory Dermatopathology by Pattern and Algorithm

- ▶ Folliculitis and perifolliculitis



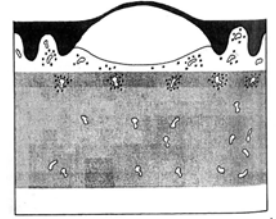
Inflammatory Dermatopathology by Pattern and Algorithm

- ▶ Intraepidermal Vesicular and Pustular Dermatitis



Inflammatory Dermatopathology by Pattern and Algorithm

- ▶ Subepidermal Vesicular Dermatitis



Patterns of cases discussed tonight

