

Case 1

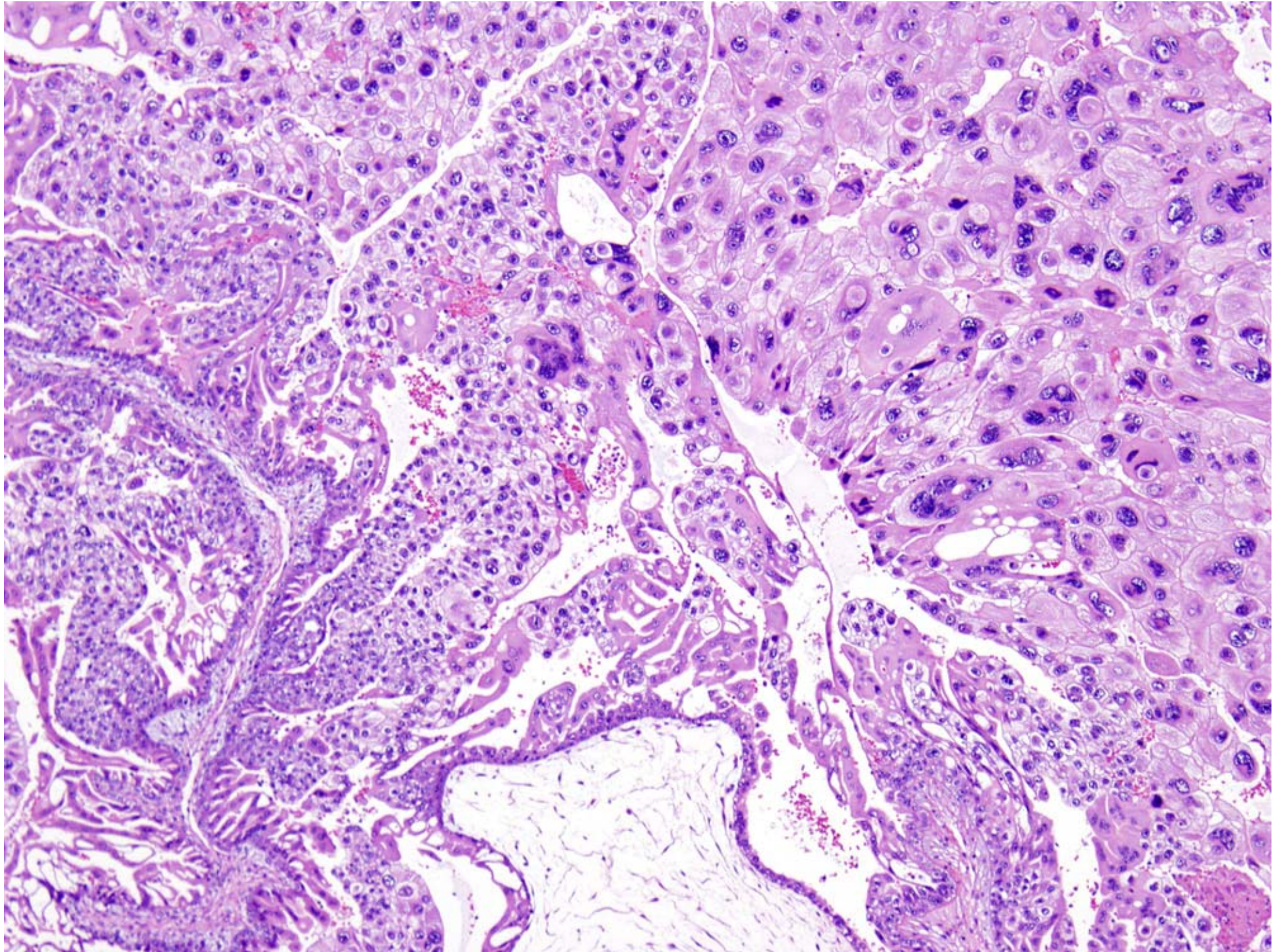
49-year-old woman

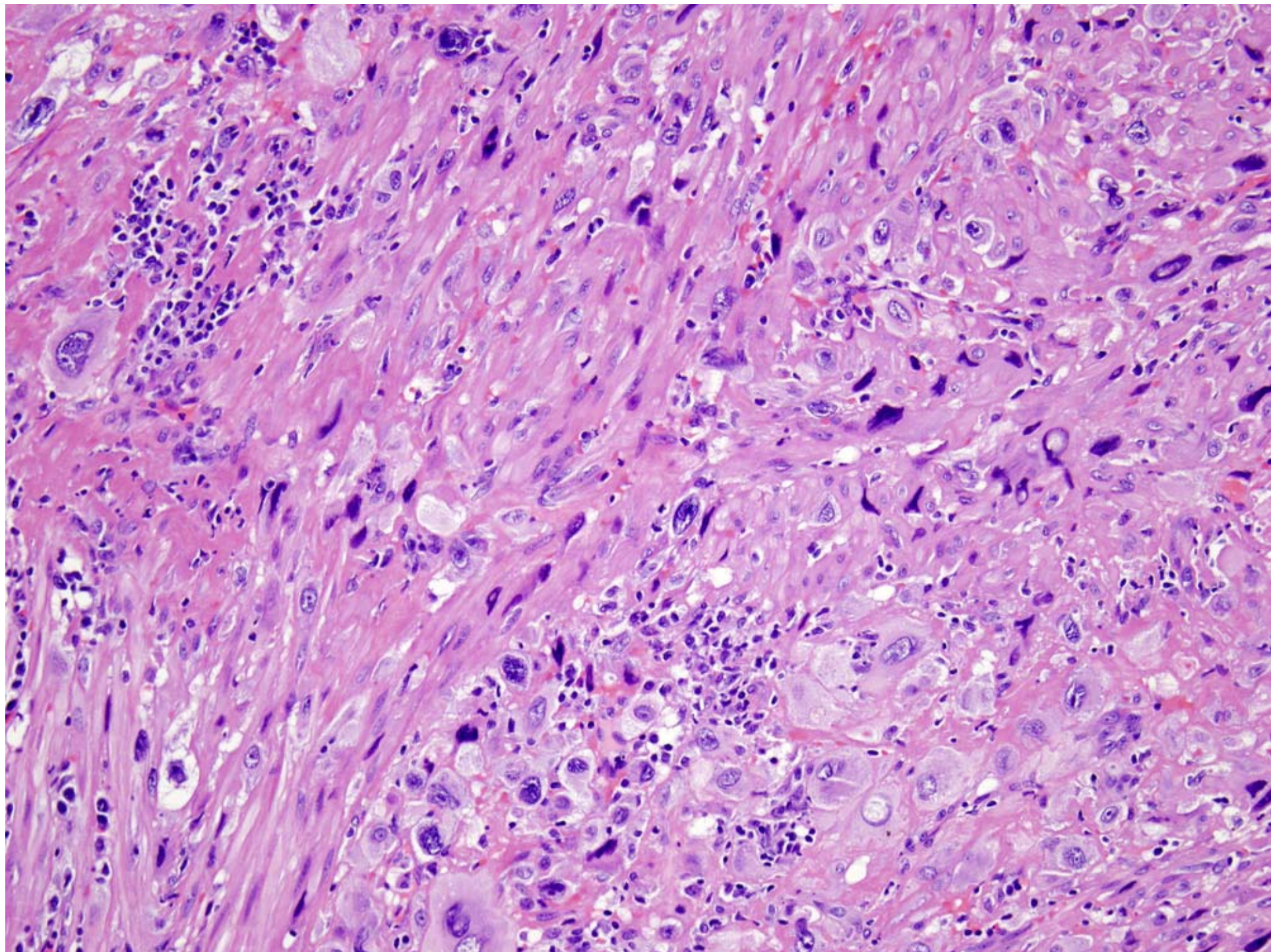
Menorrhagia

Enlarged uterus

Case 1

**2 sections from the middle
portion of the myometrium
are represented on the next
slides**





Case 1

**What test(s) would you
order?**