

LASOP  
Slide Seminar-USC  
October 11, 2011

“30 year old male presenting with a scrotal mass”

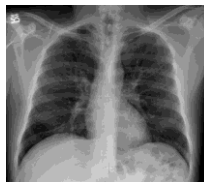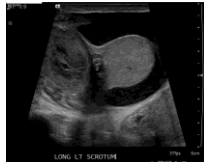Neil J. Rawlinson M.D., M.S.

Case Report - AR

- 30 yr-old male presented to LAC/USC on 7/23/11 with acute left testicular swelling and sharp pain radiating to left groin
- Pt states left testicle was normal in size 2 days prior

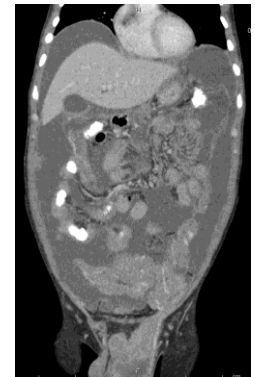
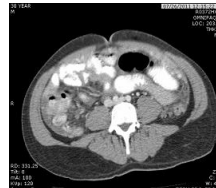Imaging

- Scrotal ultrasound
  - Left multiloculated extratesticular mass with both solid and cystic components with complex internal debris. Etiology unknown.
  - Hematoma vs epididymal lesion.
- CXR
  - hilar adenopathy.
- Chest CT
  - Pulmonary emboli.
  - Omental nodularity noted



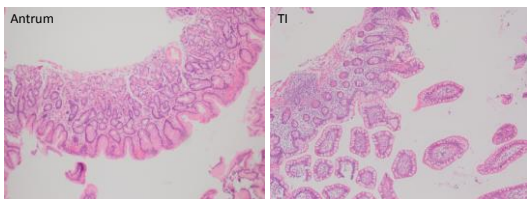
Abd & Pelvis CT

- Omental nodularity and lymphadenopathy (“omental carcinomatosis”)
- with extension of omentum into the left scrotum.



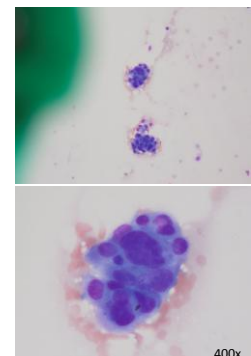
Upper endoscopy

- Antrum and terminal ileum biopsies:  
“no significant lesion”.

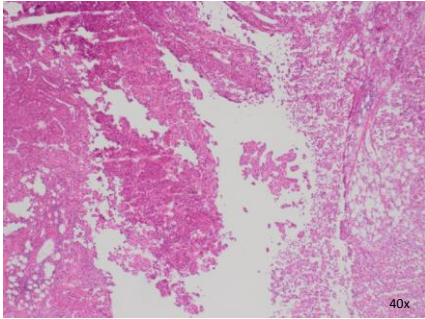


Abdominal FNA

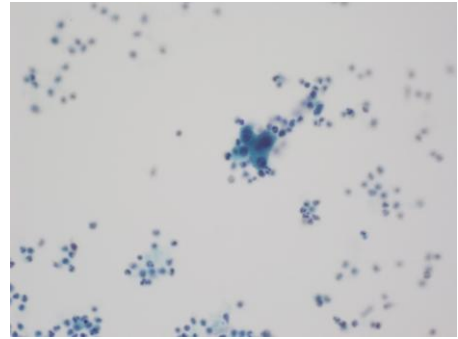
- Hypocellular specimen.
- Poorly cohesive groups and individual atypical cells with prominent hyperchromatic nucleoli.
- Dx: **Atypical cells present, Highly suspicious for malignancy.**
- Inadequate for immunostaining



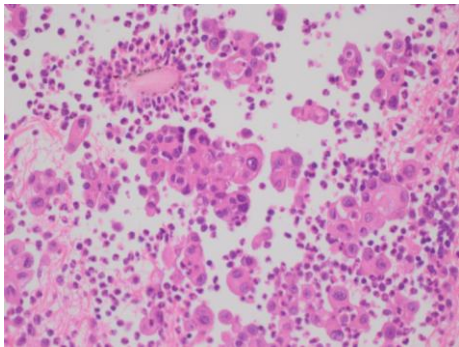
Omental biopsy  
frozen section



Ascitic Fluid



Ascitic Fluid



Omental biopsy

